

Ultrasound for the Diagnosis of Acute Appendicitis: A Hospital Based Study

SADAF AROOJ¹, MAHWASH MANSOOR², IRAM AMIR³

ABSTRACT

Aim: To evaluate the role of ultrasound for the diagnosis of acute appendicitis and decrease the negative appendicectomy.

Methods: This comparative cross-sectional study was carried out at Combined Military Hospital, Quetta from December 2007 to May 2008. Sixty patients consecutive adult patients (44 male and 16 female; the age range was 13 to 50) were examined by appendiceal transabdominal sonography with tissue harmonic imaging. After consent, history and clinical examination, ultrasound was performed. The detection rate, outer appendiceal diameter, intraluminal content, and location of the appendix were estimated. Patients were divided in appendicitis and non appendicitis groups and US detection was compared with age, sex and other variables.

Results: Patients fulfilling inclusion criteria were included in the study. The results prove that ultrasound has a sensitivity of 82.85%, specificity of 87.50%, positive predictive value of 90.62% and negative predictive value of 77.77%.

Conclusion: Ultrasonography should be used as very important adjunct to clinical examination, as it increases the sensitivity, specificity and accuracy for diagnosing appendicitis.

Keywords: Appendicitis, Ultrasound, Diagnosis

INTRODUCTION

Appendicitis is the most common cause of acute abdominal pain that necessitates surgical intervention. In 1886, Reginald H. Fitz, a Harvard pathologist, first described the clinical condition of acute appendicitis.¹ A few years later, Charles McBurney described the clinical findings prior to rupture and advocated early surgical intervention. Approximately 7% of individuals develop appendicitis at some time during their lives. Approximately 200,000 appendectomies are performed annually in the United States². The ability to make a differential diagnosis is important in patients with abdominal pain because a number of disorders can mimic the clinical signs of acute appendicitis, including gallbladder disease, acute pyelonephritis, urinary tract stone disease, infectious/inflammatory conditions of the cecum/ascending colon, and pelvic diseases such as complicated ovarian cysts, hemorrhage, and torsion^{3,4}. However, the diagnosis of appendicitis is often difficult to characterize from the normal appendix or acute appendicitis, even for the experienced examiner.⁵ Authors of large prospective studies report a 22–30% removal rate of normal appendices at surgery. To reduce the frequency of unnecessary appendectomy, the importance of

laboratory findings that include both white blood cell (WBC) counts and C-reactive protein (CRP) values has been stressed, and the use of ultrasonography as a diagnostic tool for appendicitis has been widely evaluated.^{6,7} Reported US signs of appendicitis can be grouped into the two categories of (a) appendiceal findings and (b) periappendiceal findings, which mainly include inflammatory changes in the right lower abdominal quadrant. In particular, tissue harmonic imaging (THI) has been reported to improve diagnostic image resolution compared with conventional sonography⁸⁻¹⁰.

Although cross sectional radiological studies like CT scan and MRI are evolving these days but their role remain problem solving in equivocal US findings^{11,12}. Ultrasound is an ideal noninvasive means to visualize the abdominal cavity. It is inexpensive and portable, and it can be rapidly performed with little or no patient preparation. Most importantly, it poses no ionizing radiation risk to the patient; therefore, it is particularly safe to use in children and pregnant women. On the other hand, it is operator-dependent¹³. In this background we decided to carryout the study so that patients with appendicitis can be diagnosed in emergency department and delay in surgery be minimized.

PATIENTS AND METHODS

All patients having pain right iliac fossa were referred by emergency on call surgeons. Those having any abdominopelvic operation in past, any known

¹Main XRay Department, Services Hospital Lahore,

²Department of Radiology, BMC Hospital Quetta.

³New XRay Department, Services Hospital, Lahore
Correspondence to Dr. Sadaf Arooj e-mail:
sadafarooj@hotmail.com

abdominopelvic mass/cyst in females, not fit for surgery/anesthesia and patients under 12 years of age were excluded. Immediate bedside US was performed to decrease any delay in management and avoid perforation. After consent, history and clinical examination, abdominal ultrasound was performed with Aloka Pro sound SSD 5500 Doppler sonographic machine, using 5 MHz convex probe. Then graded compression usg technique with 7.5MHz linear probe for superficial parts, was used for right iliac fossa. Inflamed appendix was identified by the following criteria: A finger shaped, blind ending, non-compressible, non-peristaltic structure on longitudinal image and target appearance on transverse scanning with minimum transverse diameter 7 mm or more. All sonographic examinations in this study were performed by 2 certified sonographers (with >5 years of experience each). In addition, positions of the terminal ileum and ileocecal valve were confirmed. The terminal ileum showed peristaltic activity and changed to an oval shape in cross section by compression. The detection rate of sonography and visualization of gas in the appendices were estimated. All outer appendiceal diameters were measured as the distance between the outer wall and the opposite outer wall (muscle coat) in a transverse section. This measurement was performed by the investigating sonographers during sonography by setting the electronic calipers in millimeters. All sonographic studies were performed with graded compression (introduced by Puylaert¹⁴) to obtain transverse and longitudinal scans. The appendix was scanned by our new technique based on systematic scanning as described below. The right major psoas muscle and iliac vessels were visualized with a transverse axial scan. Using the above image as a guide, visualized appendices were identified as the location of the ileocecal valve and distal border of the ileum. The psoas muscle and iliac vessels are the anatomic landmarks for identifying the appendix, which is usually localized between these structures and the abdominal wall.¹² If the appendix was recognized, the cecum continued with the appendix as a blind-ending structure. When the appendix was difficult to identify, transverse and longitudinal scans from the cecal portion to the hepatic flexure were added, and a search for the peripheral ascending colon was attempted. Appendiceal sonography was performed within 5 minutes, on average, after abdominal sonographic screening (Fig.1). Post surgical evaluation was done with morphology and histopathology. For patients who underwent appendectomy, the sonography findings were compared with the microscopy report as the gold standard. Of the patients with false-positive findings on sonography, each specific sonography report was

obtained and analyzed for the presence of the diagnostic criteria described earlier if the patients went to surgery. If the patient did not undergo surgery based on the surgeon's opinion, they were called later for follow-up. All selected 60 cases (fulfilling the inclusion and exclusion criteria), the findings seen on the US and pathological findings were collected. Statistical analysis was performed with SPSS version 16. The sensitivity, specificity, accuracy, positive predictive value, and negative predictive value of sonography in the detection of appendicitis were calculated.

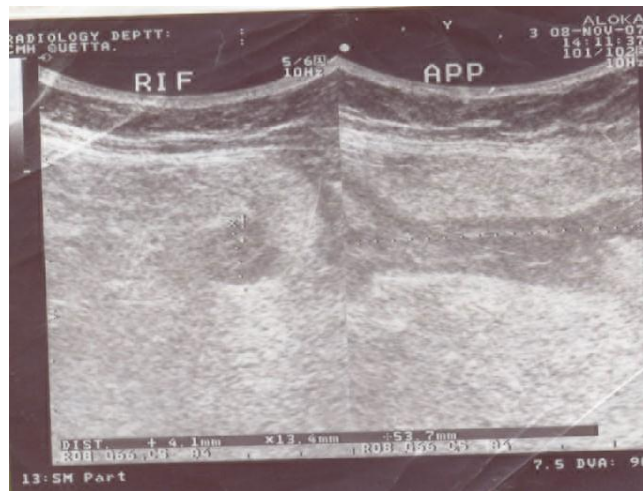


Fig.1: Transverse and longitudinal US views of inflamed appendix

RESULTS

Initially 62 patients were included in the study. Out of these 2 patients were excluded. One patient had history of congestive cardiac failure (unfit for surgery) and the other had history of laparotomy. Of the 60 patients clinically suspected of having appendicitis, 35 had acute appendicitis and 25 did not. In all 35 patients with acute appendicitis, the diagnosis was confirmed with surgery and histologic evaluation. Among the 25 patients without acute appendicitis, the diagnosis was confirmed at surgery in 2 patients, at cystoscopy and at clinical follow-up in 22 patients. The final diagnoses established in the non-appendicitis group was found to be normal (no abnormality detected) in 21 patients, 1 was found to have CA colon after surgery, 1 had right vesicoureteric junction calculus and 1 had right ovarian mass. The appendix was identified at US assessment in 29(83%) of 35 patients with appendicitis, whereas it was identified in 3(12%) of 25 patients without appendicitis (Fig. 2). Thus, our entire study group included 32(53%) patients in whom the

appendix was identified by using US and 27 patients in whom it was not identified. Of these latter 27 patients, 6 had a final diagnosis of appendicitis, thus giving the lack of visualization of the appendix at US. The 32 patients in whom the appendix was visualized constituted a group in which appendiceal US findings could be tested. Out of our 60 patients, 44 were male and 16 were females, giving a male to female ratio of 2.75:1. The age range was 13 to 50. The group 21-30 shows highest frequency of appendicitis. Table 2 shows the demographics of the study population. It also displays the statistics broken down by patient age groups. The sensitivity of US for diagnosing appendicitis determined was 82.85%, specificity of 87.50%, positive predictive value of 90.62% and negative predictive value of 77.77%.

Table 1: Histopathology ultrasonography cross-tabulation

Histopathology	Histopathology			Total
	Yes	No	Other	
Yes	29	6	-	35
No	-	21	-	21
Other	3	-	1	4
Total	32	27	1	60

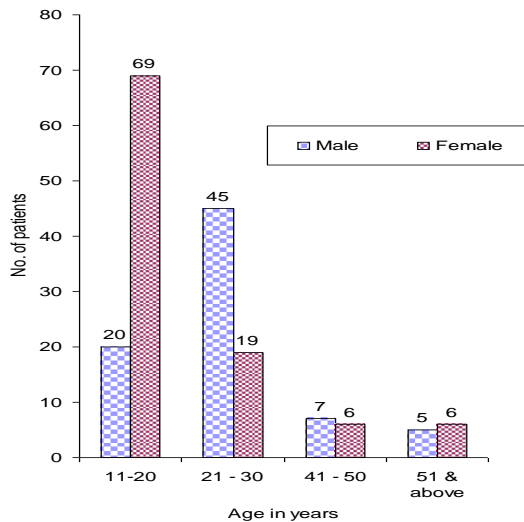


Fig.2: Distribution of genders according to age

DISCUSSION

The diagnosis of Appendicitis depends on presentation, clinical examination, US, CT scan and findings on surgery. Finally biopsies are needed for ultimate diagnosis. Our study showed Gray-scale Sonography analysis in the diagnosis of Appendicitis. In this section other studies in terms of technique, criteria and interpretation of results for diagnosing appendicitis will be discussed and compared with our study. Tissue harmonic imaging may have assisted in

visualization of the normal appendix because THI is characterized by a reduction of artifacts.³⁻⁷

In a study by Kessler N. et al¹⁵ total of 125 consecutive patients suspected of having appendicitis were prospectively included for various US parameters like increased appendiceal diameter, periappendiceal evaluation and Doppler US evaluation (appendiceal wall signal). The results were; Sensitivity 83%, Specificity 95%, Accuracy 92%, Positive predictive value 86% and Negative predictive value 94%. The laboratory and US findings were compared with surgical and pathologic results when laparotomy was performed. For all patients who did not undergo surgery, follow-up was conducted. When compared with our study, there are certain differences like they used Doppler US and Lab findings in addition to grey scale US, while we used only the grey scale US. Multiple criteria were used for detection of appendicitis e.g. peri appendiceal fat changes, diameter of 6mm or greater, dilated distal end etc, while we have used only a non compressible appendix with diameter of 7mm or more. Our study was equally sensitive but less specific.

Study by Chan¹⁶ showed all reports relating to appendicitis retrospectively obtained, were correlated with the histopathology reports. In comparison, our study was a prospective study while they had a retrospective study done in a hospital where records were well kept. Secondly, patients having normal report of US had their follow up done with CT Scan, thus confirming or excluding the diagnosis, while in our hospital set up, CT Scan is not routinely performed. They reported specificity of 95% while ours was 87.50%.

Prasad¹⁷ had a prospective study done in which 148 patients with non traumatic acute abdominal pain were included and underwent US. Definite diagnosis was made in 116 cases. Various diseases were found like cholecystitis, pancreatitis, ureteric calculus and appendicitis. Appendicitis US showed sensitivity of 66.6% and specificity of 100%. Thus our study was more sensitive and less specific. They used a wide term of "acute abdomen" while we limited our study to patients of right iliac fossa pain.

Yabunaka¹⁸ evaluated sonographic visualization of the appendix in normal patients. They classified the location of appendix in all cases and assessed the body mass index, abdominal wall thickness, age and sex with their effect on visibility of appendix. In comparison, we selected only those patients who were symptomatic. They did not compare their results with histopathology because surgery of asymptomatic patients was not possible, while we compared our results of US with histopathology which is gold standard.

Mardan et al¹⁹ had a comparison of two groups of patients with suspected appendicitis at two different hospitals at two different countries. One group comprises of patients managed without preoperative ultrasound and the other group managed with US. They showed results in term of negative appendectomy rate and rate of perforation. Their study was different as it was much complicated, studying two different groups at two different countries needs much data collection and analysis, while our study was much simpler. Our study was equally and in some cases even more sensitive but less specific when compared to others. A number of limitations of our study must be considered. First, we used grey scale US with probe frequency of 5 MHz, while others had probes of 7-10MHz increasing the resolution of images. Other methods like tissue harmonic imaging, Doppler US and CT Scan were also included by others. Secondly we had no special expertise in US of gastrointestinal tract while they had. Third, it is difficult to recognize appendix in many cases e.g. cases of self limiting, spontaneously resolving appendicitis. Lastly, we had used single criteria for detection while others used many.

CONCLUSION

In conclusion, the sensitivity, specificity, accuracy, and positive and negative predictive values of sonography performed for the detection of appendicitis are high so it should be practiced preoperatively as a routine. The other methods e.g. high resolution probe, Tissue Harmonic Imaging (THI) and colour Doppler of the right lower quadrant have become widespread in the diagnosis of acute appendicitis. CT scan is getting even more popular. US is also helpful in diagnosing alternative disease and to reduce negative laparotomy rate.

REFERENCES

1. Fitz RH. Perforating inflammation of the vermiform appendix; with special reference to its early diagnosis and treatment. *Am J Med Sci* 1886;92:321-46.
2. Lee SL, DuBois JJ, Puapong DP, Vermiform Appendix [online]2006 March 10 last update.[cited 2008 .Feb 23] Available from: URL: <http://www.emedicine.com/med/topic3327.htm>
3. Appendix: Complications [online] 2008 [cited 2008 Feb 5] available from: URL: <http://pathologyoutlines.com/appendix.html#prim>
4. Balentine J R, , Lex J R. Abdominal pain in adults [online] 2007 [cited March 12 2008]. Available from:

URL: [http://www.emedicinehealth.com/ abdominal_pain_in_adults/article_em.htm](http://www.emedicinehealth.com/abdominal_pain_in_adults/article_em.htm)

5. Incesu L, Taylor CR. Appendicitis [online] 2004 [cited 2007 March 12] Available from: URL: <http://www.emedicine.com/radio/topic47.htm>
6. Al-Khayal KA, Al-Omran MA. Computed tomography and ultrasonography in the diagnosis of equivocal acute appendicitis-a meta analysis. *Saudi Med J* 2007;28:173-80.
7. Terasawa T, Blackmore CC, Bent S, Kohlwes R J. Systematic review: Computed tomography and ultrasonography to detect acute appendicitis in adults and adolescents. *Ann Intern Med* 2004;141:537-46.
8. Lee JH, Jeong YK, Park KB, Park JK, Jeong AK, Hwang GC. Operator-dependent techniques for graded compression sonography to detect the appendix and diagnose acute appendicitis. *Am J Roentgenol* 2005; 184: 91-7.
9. Yucel C, Ozdemir H, Asik E, Oner Y, Isik S. Benefits of tissue harmonic imaging in the evaluation of abdominal and pelvic lesions. *Abdom Imaging* 2003; 28: 103-9.
10. Shapiro RS, Wagreich J, Parsons RB, Stancato-Pasik A, Yeh HC, Lao R. Tissue harmonic imaging sonography: evaluation of image quality compared with conventional sonography. *AJR Am J Roentgenol* 1998;171:1203-1206.
11. Levine PD, Eyvazzadeh AD, Siewert B, Ngo L, Rofsky NM. MR imaging evaluation of acute appendicitis in pregnancy. *Radiology* 2006; 238(3): 891-9.
12. Babri MA. Role of unenhanced CT in the evaluation of abnormal appendix – comparison with ultrasound assessment. (Dissertation Radiology). Lahore: College of Physicians and Surgeons Pakistan, 2003.
13. Old JL, Dusing RW, Yap W, Dirks J. Imaging for suspected appendicitis. *Am Fam Phys* 2005; 71: 71-8.
14. Puylaert JB. Acute appendicitis: US evaluation using graded compression. *Radiology* 1986; 158: 355-60.
15. Kessler N, Cyteval C, Gallix B, Lesnik A, Blayac PM, Pujol J, Bruel JM, Taourel P. Appendicitis: evaluation of sensitivity, specificity and predictive values of US, Doppler US, and laboratory findings. *Radiology* 2004; 230: 472-8.
16. Chan I, Bicknell SG, Graham M. Utility and diagnostic accuracy of sonography in detecting appendicitis in a community hospital. *AJR* 2005; 184: 1809-12.
17. Prasad H, Rodrigues G, Shenoy R. Role of ultrasonography In non-traumatic acute abdomen. *Internet J Radiology* 2007; 5: 19-23.
18. Yabunaka K, Katsuda T, Sanada S, Fukutomi T. Sonographic appearance of the normal appendix in adults [online] 2006 [cited 2008 May11] Available from: URL:<http://www.jultrasoundmed.org/cgi/content/full/26/1/37>
19. Mardan MAA, Mufti TS, Khattak I, Chikunda N, Alshayeb AA, Muhammad AM, et al. Role of ultrasound in acute appendicitis. *J Ayub Med Coll* 2007; 19(3): 43-9.